

**Thrombocytopenia Caused by Pregabalin and Possibly Mirogabalin
Administered for Herpes Zoster Pain: A Case Report**

Keiko KAWANO, Tatsuya KAMINOSONO, Masayuki NAGANO

Thrombocytopenia Caused by Pregabalin and Possibly Mirogabalin Administered for Herpes Zoster Pain: A Case Report

Keiko KAWANO*, Tatsuya KAMINOSONO, Masayuki NAGANO

Department of Anesthesiology, Tenyoukai Central Hospital

(Received 2 March 2020; Revised 11 November 2020; Accepted 17 November 2020)

* Address to correspondence

Keiko KAWANO

Department of Anesthesiology, Tenyoukai Central Hospital

6-7 Izumi-Cho, Kagoshima-City, Kagoshima, Japan, 892-0822,

Phone:+81-99-226-8181

FAX:+81-99-224-2752

e-mail: heykawkey@gmail.com

Abstract

A 68-year-old woman developed pain in the left lateral region of her abdomen, and three days later, rashes appeared at the T11 level on her left side (day 0). On day 9 after the onset of rash, she consulted a primary doctor and was given loxoprofen. Subsequently, she visited our hospital because of severe persistent pain on day 12 and was administered 150-300 mg/day of pregabalin, which was given from day 12 to day 43. Her platelet count continued to decrease from $18.1 \times 10^4/\mu\text{L}$ to $8.8 \times 10^4/\mu\text{L}$ under 100-300 mg/day of pregabalin. Reducing the dose of pregabalin to 50 mg seemed to increase the platelet count to $10.9 \times 10^4/\mu\text{L}$ on days 40-43. On day 43, pregabalin was switched to 10 mg/day of mirogabalin. Although we initiated mirogabalin, the platelet count was further reduced to $6.5 \times 10^4/\mu\text{L}$ on the fifth day of treatment. After mirogabalin was discontinued, the platelet count started to recover rapidly up to $17.2 \times 10^4/\mu\text{L}$ until day 63. During this course of treatment, 0.2% ropivacaine was administered through an epidural catheter from day 20 to day 60, 20 mg/day of duloxetine was also given, and 200 mg/day of carbamazepine was continued throughout from day 28 and from day 37. The alteration in the patient's platelet count seemed to be unrelated to epidural analgesia, duloxetine, and carbamazepine because the platelet count recovered to normal levels without discontinuing these drugs. In summary, we herein report a case of thrombocytopenia caused by pregabalin and possibly mirogabalin.

Key words: Pregabalin, Mirogabalin, adverse drug effect, thrombocytopenia, herpes zoster

Introduction

Pregabalin is a widely used drug for neuropathic pain. The main sites of pregabalin action are the presynaptic $\alpha_2\delta$ subunits of voltage-gated calcium channels, which are distributed throughout the peripheral and central nervous system¹⁾. Mirogabalin has high binding affinities for the $\alpha_2\delta$ subunits and

yields fewer adverse reactions of a neuropsychiatric nature²⁾. Mirogabalin appeared on the market after pregabalin and was characterized by fewer neuropathic side effects than pregabalin.

According to the Pharmaceutical Interview Forms of Japan, thrombocytopenia as a side effect of pregabalin has been reported in 2 out of 1,860 cases, and its incidence is estimated to be 0.3%-

1%³⁾. Data from France have indicated a rate of 0.29%⁴⁾. In contrast, no cases of mirogabalin-induced thrombocytopenia have been reported.

We report a case of thrombocytopenia in a patient following the administration of pregabalin and mirogabalin to relieve herpes zoster pain. Here, we describe the course of events of the case.

Case Presentation

Written informed consent was obtained from the patient for publication of this case.

The patient was a 68-year-old female with a height of 150 cm and body weight of 64 kg. She had no relevant medical or family history.

The patient had been healthy since birth and had never developed any significant illnesses. However, she had recently developed pain in the left lateral region of the abdomen, and three days later, rashes

appeared that extended from the left lateral region of the abdomen to the left side of the dorsum (day 0). On day 9 after the onset of rash, she consulted a primary doctor and was diagnosed with herpes zoster. Loxoprofen was orally administered for three days, but no antiviral agents were provided. On day 12, the patient visited our hospital because of severe persistent pain. Physical examination revealed pain due to herpes zoster on the left side at the T11 level. As her serum creatinine level and estimated glomerular filtration rate were 0.49 mg/dl and 93.2 ml/min, we administered 150–300 mg/day pregabalin. Despite the administration of pregabalin, the patient's visual analogue scale (VAS) score was 81/100. On day 19, she was admitted to our hospital for pain relief. At the time of admission, scarring was observed in most of the region with rashes. Furthermore, the patient complained of persistent spontaneous pain and haphalgnesia at the site. Vital signs were within the normal range.

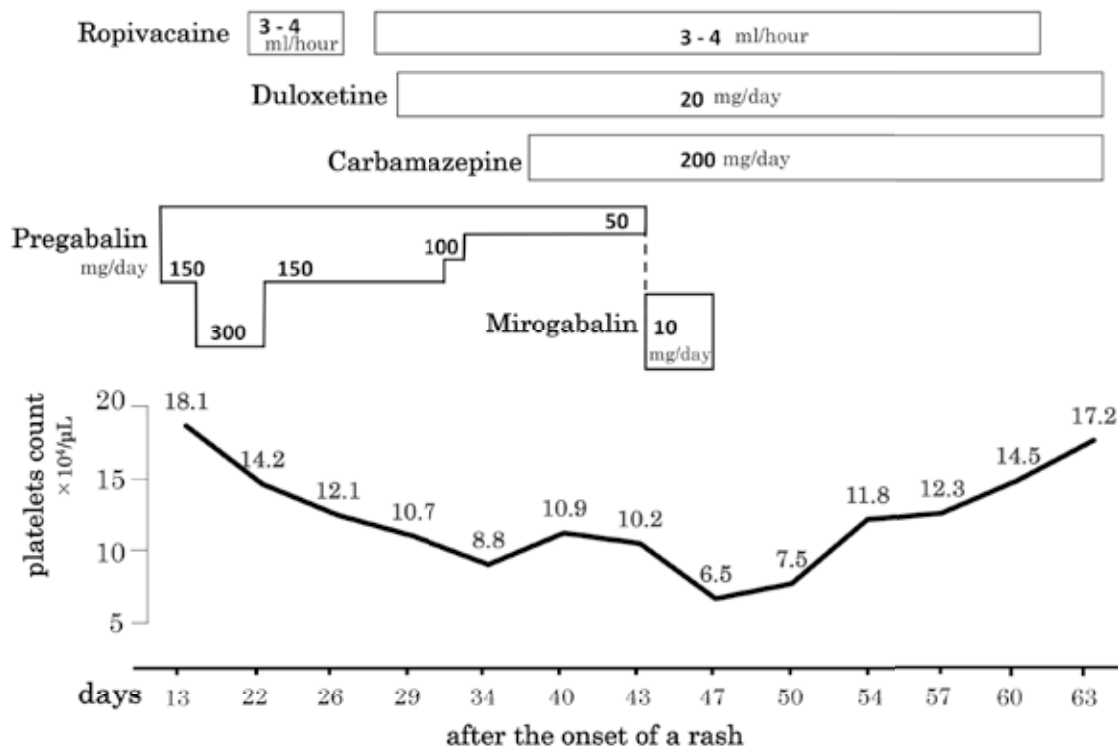


Figure 1, Clinical course of drug administration and alternation of platelet count from day 13 to day 63 after onset of Varicella-Zoster rash. Continuous epidural infusion of 0.2% ropivacaine was performed on days 20~26 and days 29~ 54.

Fig. 1 shows the treatment course and alteration in the platelet count. On day 20, an indwelling epidural catheter was placed at Th9/10. As the patient had local dermatitis on the dorsum, the indwelling epidural catheter could not be placed in the optimal position. A continuous epidural infusion of 4 ml/hr of 0.2% ropivacaine alone was administered via the catheter at an infusion rate of 3-4 mL/h. Subsequently, the patient's VAS score changed from 81/100 to 46/100. Epidural analgesia was performed daily from days 20 to 60. Therefore, sufficient efficacy could not be obtained; hence, on admission, 300 mg/day of pregabalin was orally administered. However, the patient experienced somnolence and abnormal thoughts, which was probably caused by pregabalin. The dose of pregabalin was gradually reduced as follows: 150 mg/day on day 22, 100 mg/day on day 32, and 50 mg/day on day 41. During that period, duloxetine and carbamazepine were added. The physician noticed that the platelet count had decreased from $18.1 \times 10^4/\mu\text{L}$ to $8.8 \times 10^4/\mu\text{L}$ and then had recovered due to the decreasing dose of pregabalin. Pregabalin-induced thrombocytopenia was suspected at that time. Consequently, pregabalin was discontinued on day 42, and 5 mg/day of mirogabalin was started. Five days later, the patient's platelet count was $6.5 \times 10^4/\mu\text{L}$. We suspected that mirogabalin was also inducing thrombocytopenia; therefore, mirogabalin was discontinued on day 45.

On day 13, the patient's platelet count was $18.1 \times 10^4/\mu\text{L}$. It was reduced to $8.8 \times 10^4/\mu\text{L}$ during the course of pregabalin administration. Five days after pregabalin was switched to mirogabalin, the platelet count decreased to $6.5 \times 10^4/\mu\text{L}$. After the discontinuation of mirogabalin, the platelet count recovered to $17.2 \times 10^4/\mu\text{L}$ on day 63. Most likely, the immediate discontinuation of mirogabalin avoided severe thrombocytopenia.

After mirogabalin discontinuation, pain relief at a VAS score of 34/100 was obtained by epidural analgesia and the administration of duloxetine and carbamazepine. During hospitalization, 20 mg/day of duloxetine was concomitantly administered from day 28, and 200 mg/day of carbamazepine was administered from day 37. However, the

platelet count improved without a discontinuation or dose reduction of duloxetine or carbamazepine. Continuous epidural infusion of 0.2% ropivacaine was performed on days 20~26 and days 29~54. No elevation in hepatic enzyme levels was observed during the hospitalization period. No hepatic disease or splenomegaly was observed on abdominal ultrasound on day 50. Moreover, no signs of bleeding were observed during the disease course, and no significant changes in white blood cell counts, C-reactive protein or red blood cell counts were observed during that period.

Discussion

Bates et al. (2008) first reported pregabalin-induced thrombocytopenia in a 91-year-old female⁵. According to a database from France, the incidence of pregabalin-induced haematologic side effects is 6.9%, and 23.6% of the cases include thrombocytopenia³. Regarding the outcome of thrombocytopenia, 68.4% of the patients recovered without sequelae.

As mirogabalin is a newly approved drug that was first used in April 2019 in Japan, thrombocytopenia has not often been reported as a side effect. A search of MEDLINE, EMBASE, International Pharmacological Abstracts, Reaction Weekly, and Drug Information for mirogabalin (from April 2019 to July 2020) with the search terms "mirogabalin" and "thrombocytopenia" yielded no published cases. Therefore, this is probably the first published report of mirogabalin-induced thrombocytopenia.

We judge that the doses of pregabalin and mirogabalin were appropriate, as renal function was normal and no adverse effects, such as thrombocytopenia, were observed.

For the treatment of pain, several concomitant drugs are generally employed. Likewise, in the present case, we used concomitant drugs, such as oral carbamazepine, duloxetine and epidural ropivacaine. The incidence of carbamazepine-induced immunological thrombocytopenia is reported relatively high⁶. However, progression of thrombocytopenia was evident before the oral administration of 200 mg/day carbamazepine. A

recovery in the platelet count was observed after the discontinuation of mirogabalin, without the discontinuation of carbamazepine. Therefore, it is unlikely that carbamazepine was associated with thrombocytopenia in the present case. Additionally, thrombocytopenia has not been reported as a side effect of duloxetine or ropivacaine, and the platelet count improved by neither discontinuing nor decreasing these drugs. Therefore, it was concluded that there was limited association between these drugs and thrombocytopenia in this case.

In addition, patients with varicella-zoster virus (VZV) infection are known to develop thrombocytopenia. In case reports^{7) 8)} of idiopathic thrombocytopenic purpura (ITP) following VZV infection, the incidence of acute ITP among people with VZV infection was 1.9%. The onset of acute ITP was observed after an average of 8.5 days from the onset of rash (range 2–30). The symptoms of chronic ITP persisted for more than 3 months⁷⁾. Among 11 patients who developed ITP following VZV infection, 4 showed acute ITP and 7 exhibited chronic ITP. Another study reported that acute ITP was caused by an immunological mechanism, namely, the cross-immunity between VZV and the antigens on the platelet membranes⁷⁾. However, that study investigated thrombocytopenia in cases of chickenpox, which is the initial infection of VZV. There are reports of the onset of thrombocytopenia occurring three days⁹⁾ and ten days¹⁰⁾ after the onset of the herpes zoster rash. It appears that the onset of herpes zoster infection caused by VZV relapse occurs slightly earlier than that of chickenpox. Thrombocytopenia became evident in the present case 22 days after rash onset; hence, it seems much more likely that the thrombocytopenia observed here was not caused by herpes zoster but by pregabalin and mirogabalin.

Both pregabalin and mirogabalin, having similar structures, have high affinities for the $\alpha_2\delta$ subunits of the calcium channels. Therefore, the two drugs may induce thrombocytopenia in a similar manner.

An immune-mediated mechanism is considered responsible for pregabalin- and mirogabalin-induced

thrombocytopenia. The hypothesis is that drug-induced immune thrombocytopenia occurs through changes in the affinity for platelet antibodies. While platelet antibodies exist in the human body to provide innate immunity, most platelet antibodies have a weak affinity for glycoproteins on the platelet surface. Therefore, normally, antigens on platelet membranes are rarely bound to these antibodies. A complementary interaction between a causal drug and platelet antibodies at the structural or electric charge level increases their affinity for platelet antigens on the platelet membranes⁷⁾. Therefore, to develop drug-induced thrombocytopenia, it is necessary for the patient to be consecutively exposed to the causal drug for 5-7 days. After discontinuation of the drug, its amount decreases in the body, and the platelet count immediately improves. Aster reported a decreased platelet count in a 29-year-old patient from day 7 following administration of the causal drug⁶⁾. The platelet count recovered to its normal level within 7 days of drug discontinuation. In the present case, the platelet count was normal up to 2 days after pregabalin administration. However, it was reduced on day 9 of continuous administration and further reduced with additional continuous administration. The platelet count recovered immediately after drug discontinuation. In the present case, decreasing pregabalin from day 32 and discontinuing mirogabalin from day 47 seemed to cause immediate recovery of the platelet count.

Although thrombocytopenia occurred in the present case, no reductions in the white blood cell or red blood cell count were observed (Fig. 1), and no elevation in the C-reactive protein level was observed. Moreover, the patient's rashes healed, except for a small area on the dorsum. Therefore, it is possible that the acute herpes zoster infection resolved. The platelet count in the present case was not related to the inflammation mechanism or bone marrow activity.

The platelet count started to recover from day 34. For only five days after mirogabalin was administered, the platelet count had decreased from $10.2 \times 10^4/\mu\text{L}$ to $6.5 \times 10^4/\mu\text{L}$, which probably was related to both the discontinued pregabalin and the added mirogabalin.

Retrospectively, mirogabalin seemed to further decrease the platelet counts.

In cases of severe thrombocytopenia, all medications should generally be discontinued. However, this would not have been ideal in the present patient because of severe pain resulting from the discontinuation. We suspected strongly, in this case, that pregabalin and mirogabalin were the causative drugs of thrombocytopenia because of the observed relationship between the dose of the medicine and the platelet count, as shown in Fig 1. Other medications, such as ropivacaine, duloxetine, and carbamazepine, did not seem to affect the platelet count. We noticed that the doses of pregabalin and mirogabalin seemed to influence the alteration in the platelet count. Therefore, only mirogabalin (and not ropivacaine, duloxetine, or carbamazepine) was discontinued on day 47. The platelet count started improving after the discontinuation of mirogabalin and recovered completely after day 47, that is, subsequent to the discontinuation of both pregabalin and mirogabalin. Therefore, we conclude that the thrombocytopenia observed in the current case was caused by pregabalin and possibly mirogabalin.

Conclusion

Based on the results of this study, we report a case of thrombocytopenia caused by pregabalin and possibly mirogabalin. Pregabalin has already been reported to induce thrombocytopenia in many cases, but mirogabalin has not yet been reported in this regard. The present study may be the first to show that mirogabalin yields thrombocytopenia as an adverse effect.

Furthermore, clinicians need to be aware of the alteration in platelet counts that may accompany not only HSV infection but also analgesic drug therapy in cases of herpes zoster.

COI Disclosure

The authors have no conflicts of interest to disclose.

References

- 1) Gajraj NM. Pregabalin: its pharmacology and use in pain management. *Anesthesia & Analgesia*. 2007;105:1805-1815.
- 2) Domon Y, Arakawa N, Inoue T, et al. Binding characteristics and analgesic effects of mirogabalin, a novel ligand for the $\alpha 2\delta$ subunit of voltage-gated calcium channels. *J Pharmacol Exp Ther* 2018;365:573-582.
- 3) Pharmaceutical Interview Forms, Pregabalin capsules/OD tablets; 2018. p136-138. Pfizer. in Japanese
- 4) Fuzier R, Serres I, Guitton E. Adverse drug reactions to Gabapentin and Pregabalin. *Drug Safety* 2013;36:55-62.
- 5) Bates D, Kirby S, Louw A. Thrombocytopenia possibly induced by pregabalin. A Review of the French Pharmacovigilance database. *Can J Hosp Pharm* 2008;6:446-447.
- 6) Aster RH, Bougie DW. Drug-induced immune thrombocytopenia. *N Engl J Med* 2007;357:580-587.
- 7) Amir A, Gilad O, Yacobovich J, Scheuerman O, Tamary H, Garty BZ. Post-varicella thrombocytopenic purpura. *Acta Paediatrica* 2010;99:1385-1388.
- 8) Wright JF, Blanchette VS, Wang H, et al. Freedman J. Characterization of platelet-reactive antibodies in children with varicella-associated acute immune thrombocytopenic purpura (ITP). *Br J Haematol* 1996;95:145-152.
- 9) Shingh N, Gayowski T, Yu V. Herpes zoster-associated idiopathic thrombocytopenic purpura in a liver transport recipient: a case report and overview. *Transpl Int* 1995; 8:58-60.
- 10) Maruchi E, Kimura S, Hozumi S, Ikegami R. A case of herpes zoster with sudden thrombopenia. *Rinsho Hihuka*. 2009;63:65-67, in Japanese.

帯状疱疹神経痛患者へのプレガバリンとおそらくはミロガバリン投与によって引き起こされた血小板減少の一症例

河野恵子, 長野真行, 上之蘭達也

天陽会中央病院 麻酔科

和文抄録

症例は、68才女性。左側腹部に疼痛出現し、その3日後、左Th11の帯状疱疹が出現 (day 0)。近医を受診、鎮痛剤の投与を受けた。疼痛が増悪するため、皮疹発現後12日目 (day 12)、当院を受診。プレガバリン内服を開始、入院治療となった。プレガバリンは投与量50~300mg/日でday43まで投与された。初診時は $18.1 \times 10^4 / \mu\text{L}$ であった血小板は、プレガバリン投与中は減少していき $8.8 \times 10^4 / \mu\text{L}$ まで低下をみた。プレガバリンを300mg/日から150mg/日 (day 22)、100mg/日 (day 32)、50mg/日 (day 41) と減量するにつれ血小板は $10.9 \times 10^4 / \mu\text{L}$ まで回復をみた。Day 43で投与量50mg/日であったプレガバリンは中止しミロガバリン10mg/日を開始したが、ミロガバリン投与5日目 (day 50) の血小板数は $6.5 \times 10^4 / \mu\text{L}$ まで減少していた。すぐにミロガバリンを中止したところ、中止3日後には、血小板数は $7.5 \times 10^4 / \mu\text{L}$ と回復し始め、以後、漸次増加をみた。ミロガバリン中止後16日目 (day 63) には血小板数は、 $17.2 \times 10^4 / \mu\text{L}$ と正常範囲に達した。入院中はday 20 ~ day 60の間、0.2%ロピバカイン持続投与による持続硬膜外ブロック.0を併用した。また、day 20よりデュロキセチン20 mg/日を、day 28よりカルバマゼピン200mg/日を開始し継続した。持続硬膜外ブロック、デュロキセチン、カルバマゼピンは同量が投与継続されたままであり減量することなく血小板数の正常範囲内への回復がみられことから、血小板減少に対して硬膜外ブロックやこれらの薬剤の関与はなかったと判断した。プレガバリン、ミロガバリン投与によって血小板減少がみられ、両者の中止によって速やかに改善したことにより、今回の症例において、血小板減少はプレガバリンによって引き起こされた可能性があり、おそらくミロガバリンも関与していたと考えられる。